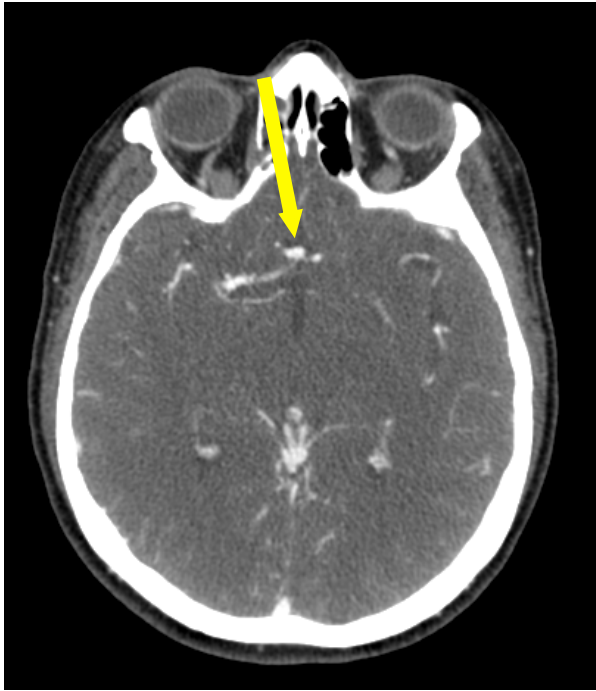


**Emergency Treatment of a
Ruptured Anterior Communicating
Artery Aneurysm via Balloon
Assisted Coiling**

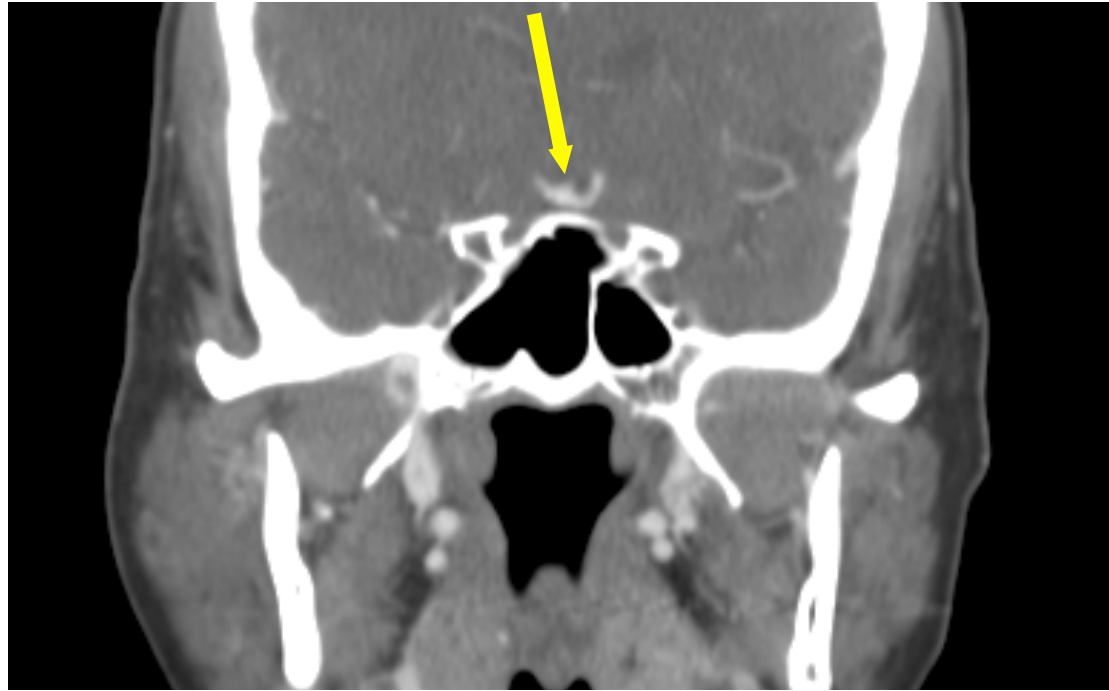
Clinical presentation

- 69 y/o female with a 3 day history of posterior cervical pain and posterior headache.
- On 8/13/15 at 2:30 PM she presented with sudden severe worsening of her pain, reported as 10/10 with some photophobia and dizziness
- EMS contacted
- Patient brought to the Umass ED
- She was alert, somnolient but arousable with no gross motor or sensitive deficit

CT of the head from 3 years prior to current admission

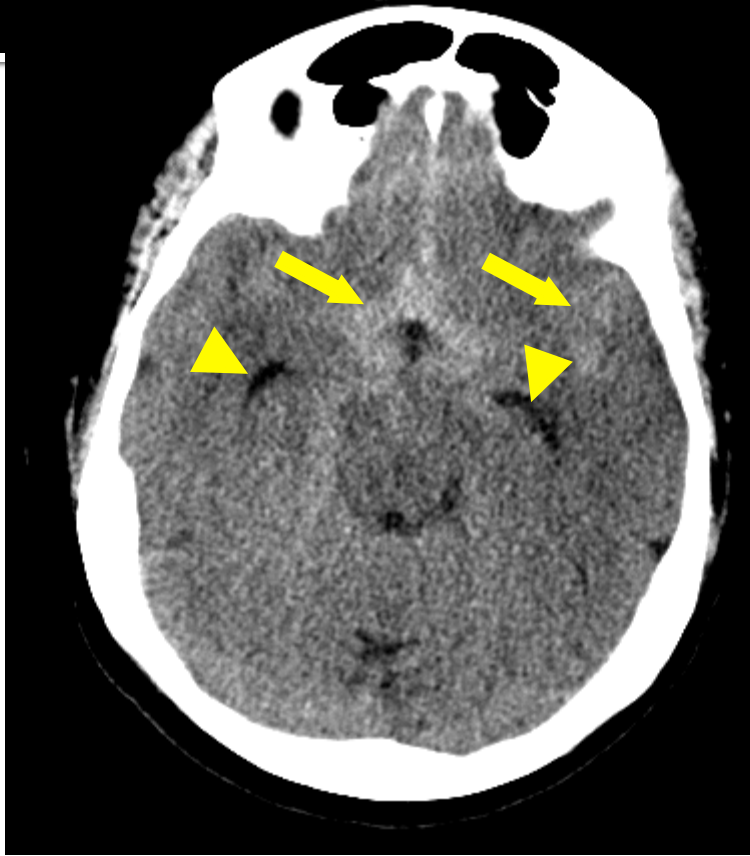

Axial CT image of the head demonstrated a bulbous appearance of the anterior communicating artery

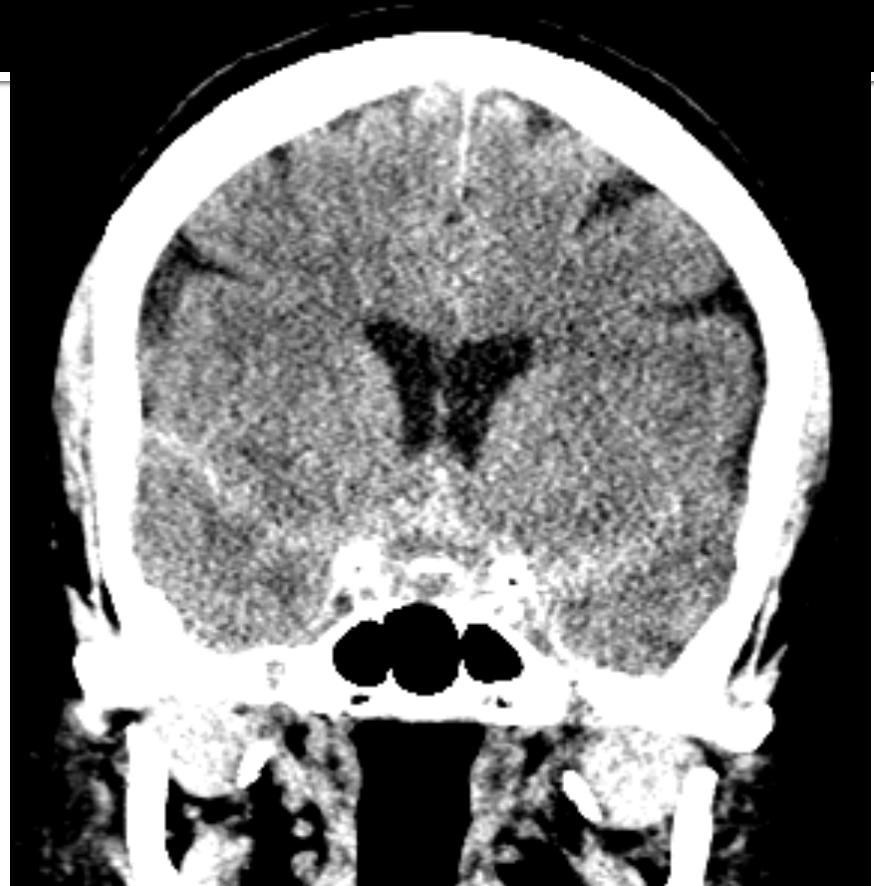

Coronal CT reconstructed image of the neck which partially included the head demonstrated again the bulbous appearance of the anterior communicating artery. This was consistent with a small blister-like aneurysm.

Admission Noncontrast CT of the head

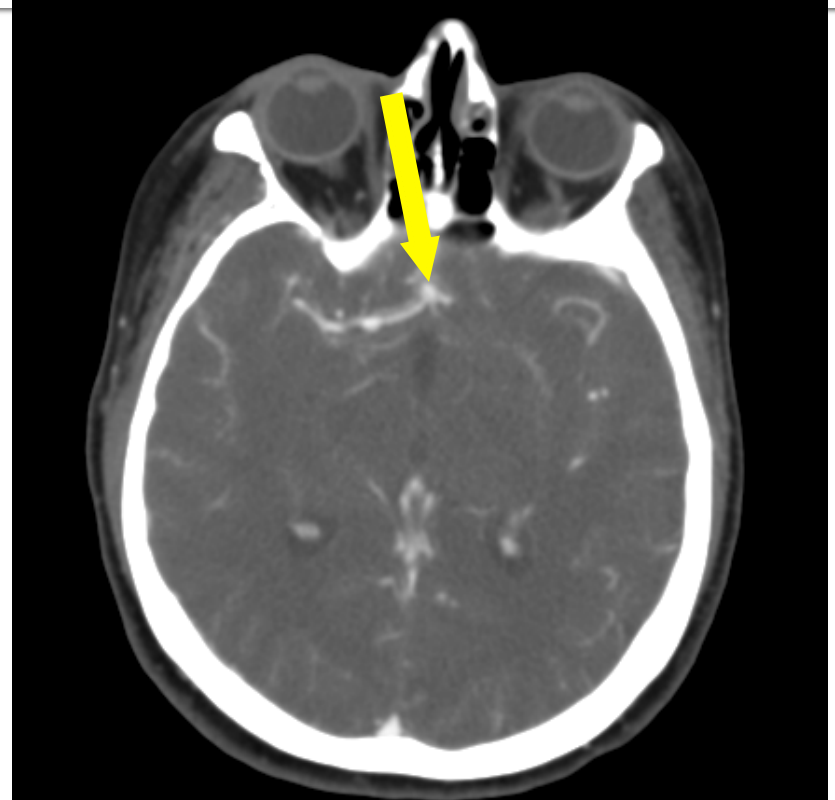
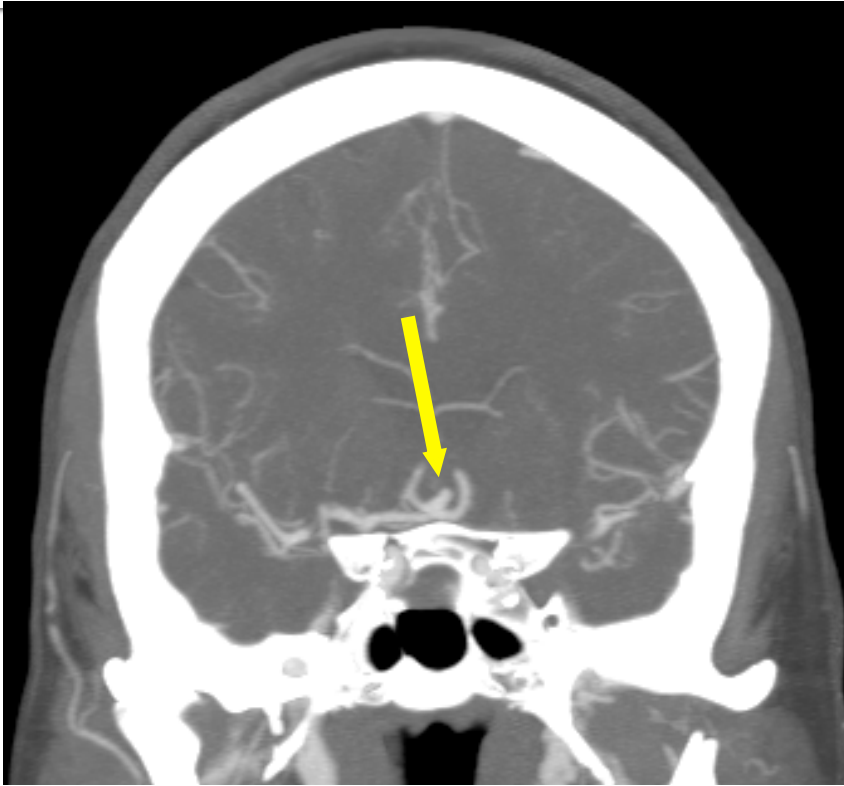


Axial CT image of the head demonstrating diffuse subarachnoid hemorrhage in the basal and Sylvian cisterns (yellow arrows). Also, mild hydrocephalus (yellow arrowheads)



Coronal CT reconstructed image of the head demonstrating the SAH

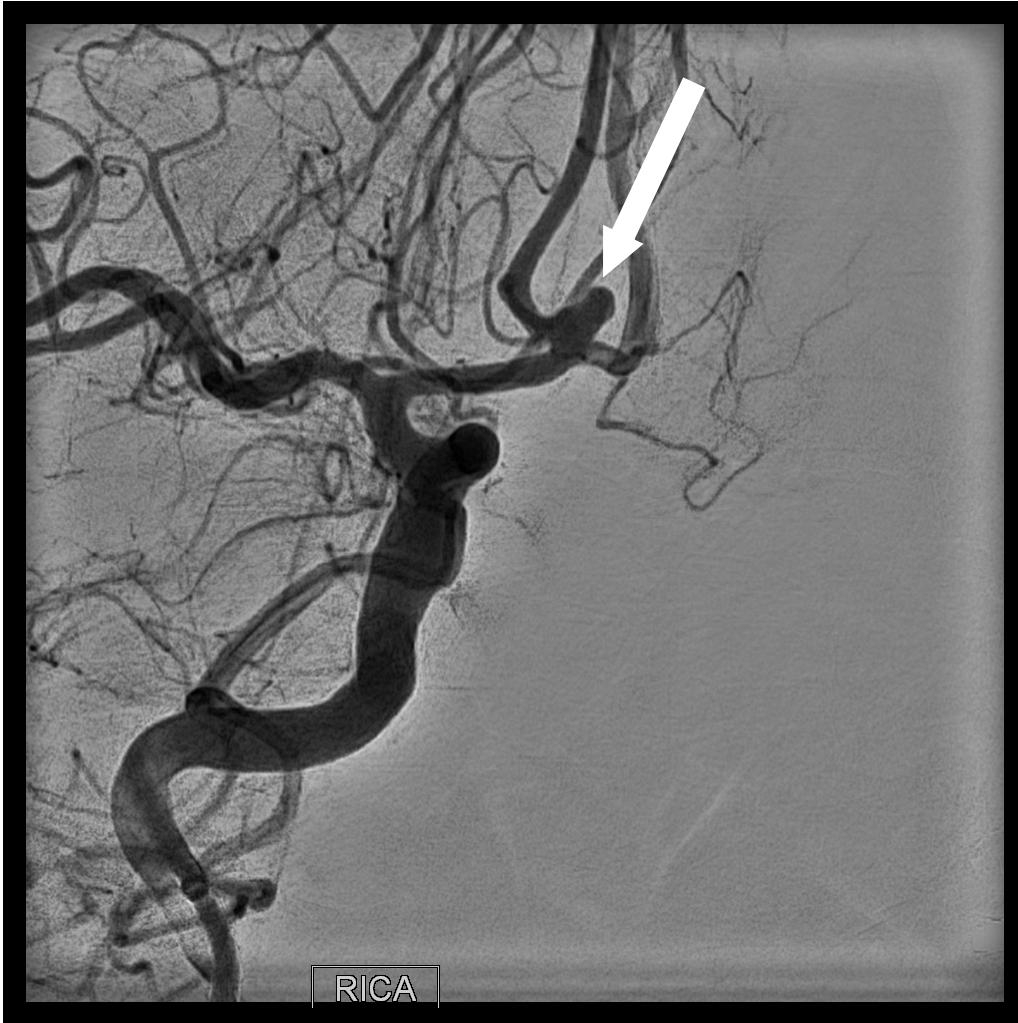Admission CTA of the head



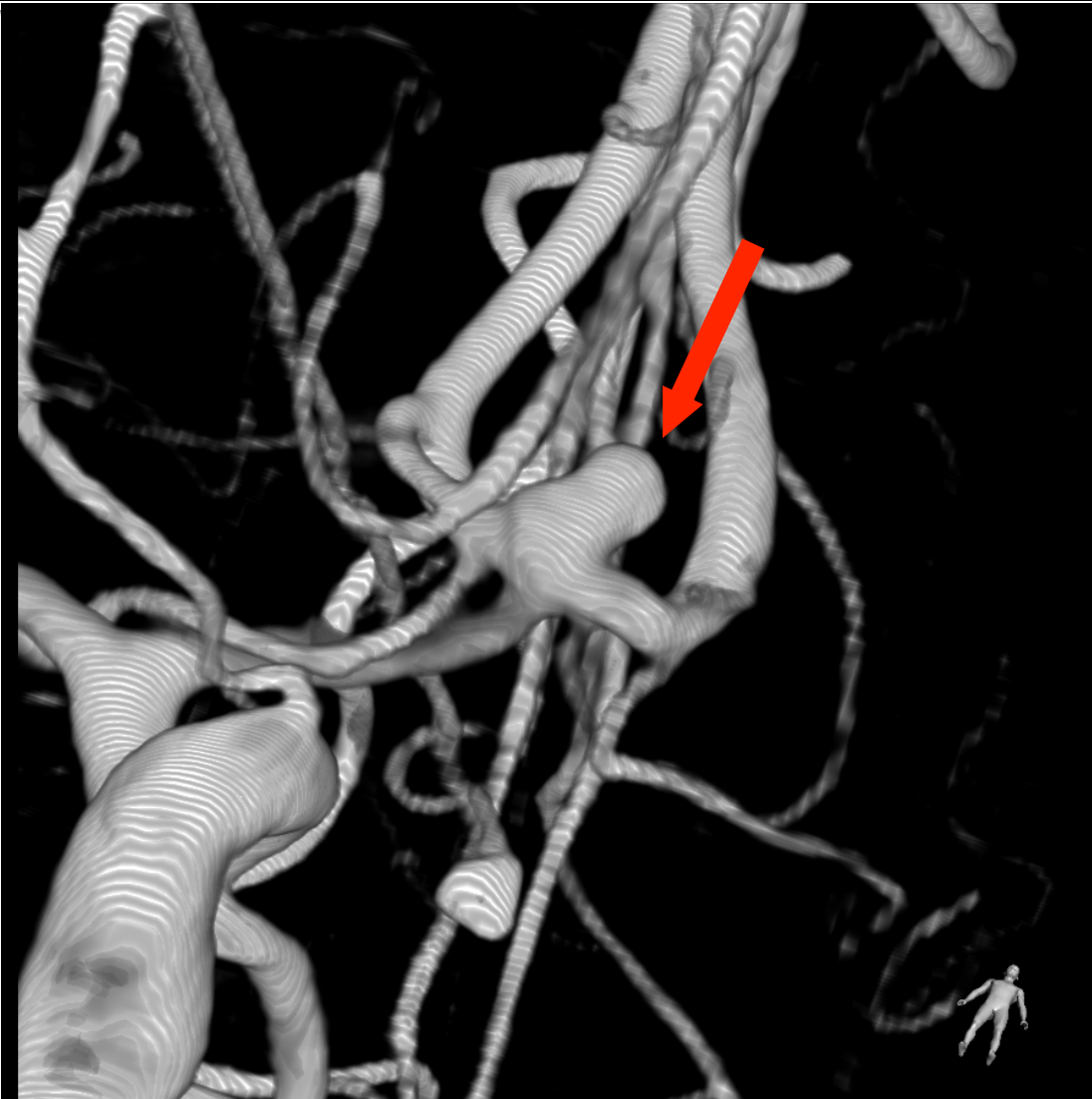A 4 mm anterior communicating artery aneurysm pointing superiorly, anteriorly and right laterally, likely the source of the intracranial bleed (yellow arrows). When compared to the prior CT of the head from 3 years ago, there has been significant interval growth of this aneurysm

Diagnosis

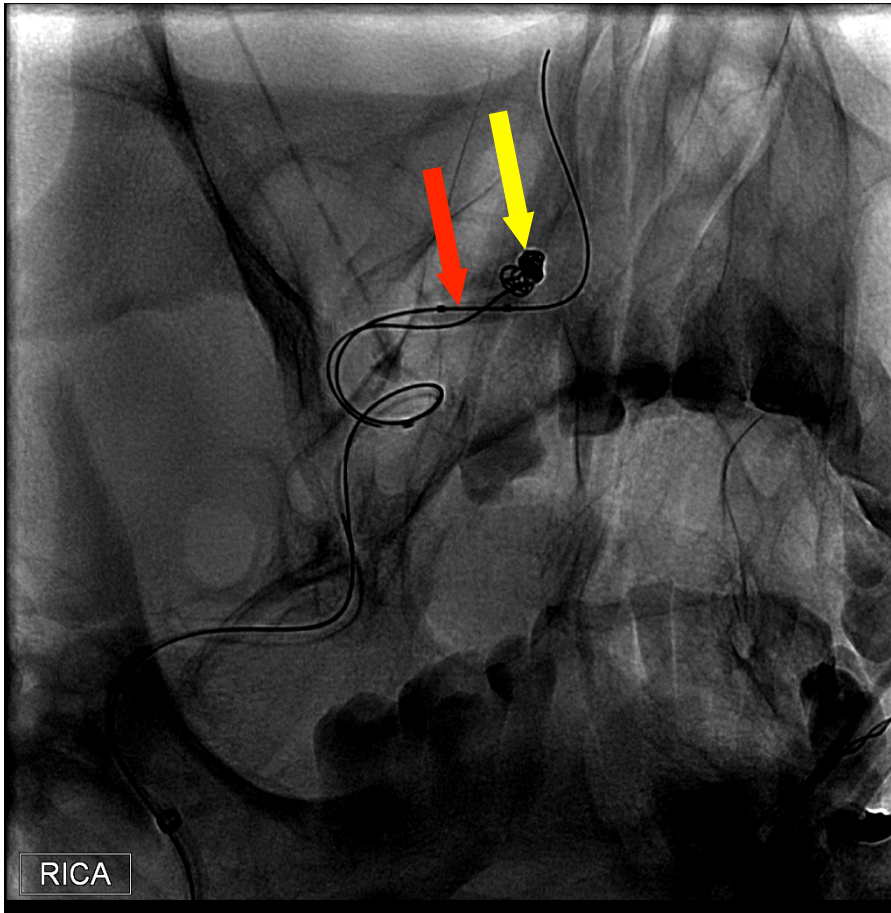
- Acute rupture of an anterior communicating artery aneurysm with secondary subarachnoid hemorrhage, Hunt & Hess 2
- Plan for treatment:
 - Neurosurgery to place an extraventricular drainage catheter for treatment of hydrocephalus and intracranial pressure monitoring.
 - NeuroInterventional Radiology consulted. Plan is to characterize the aneurysm and outline treatment accordingly



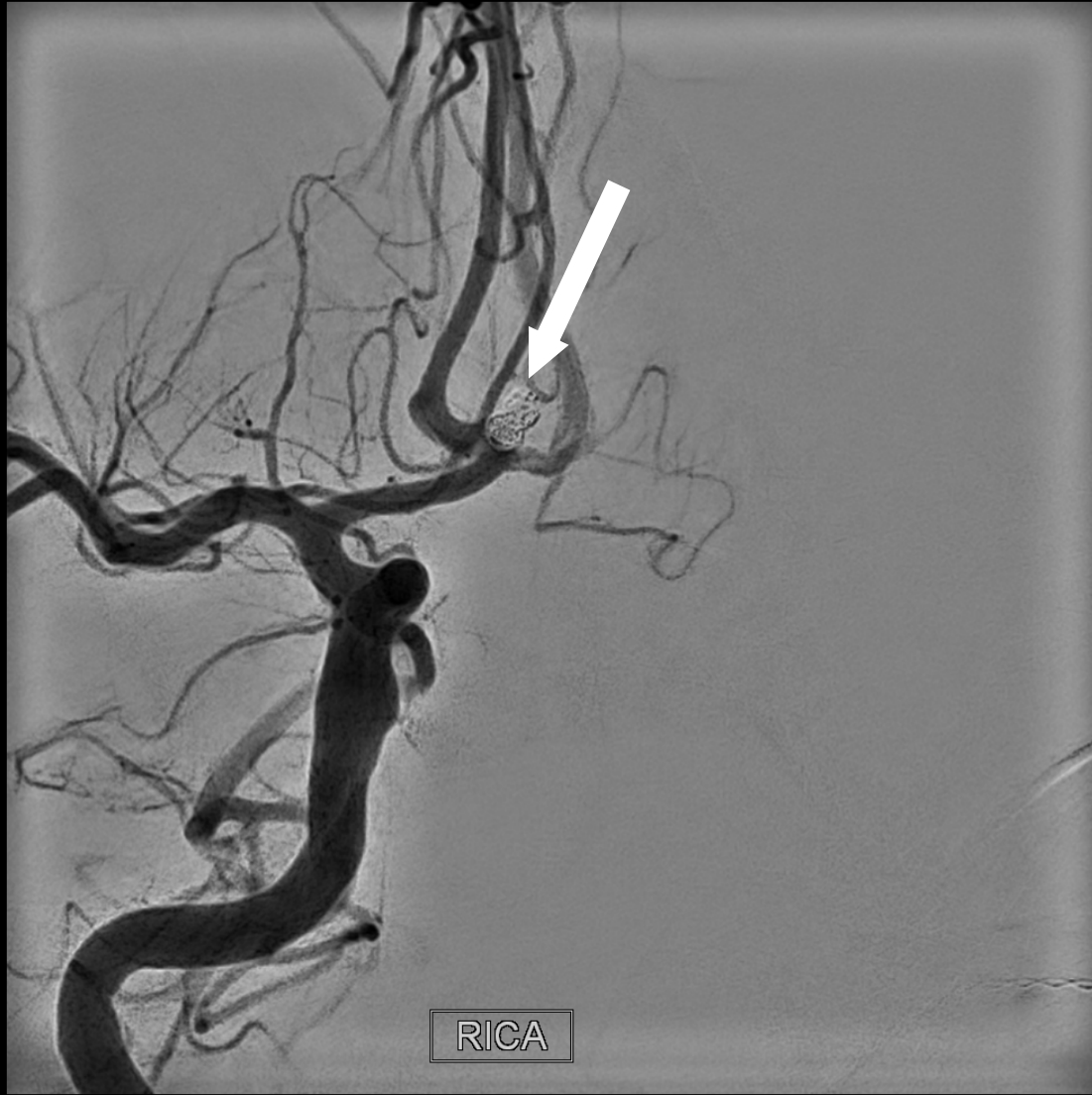Digital subtraction
angiographic
magnified oblique view
of the anterior
communicating artery
aneurysm (white
arrow).



3-Dimensional C-arm rotational Angiogram performed on the NeuroInterventional Suite further characterizes the ruptured aneurysm (red arrow) and the vascular anatomy to plan treatment. Note the low dome to neck ratio and wide neck. An adjunctive device, likely a balloon, will be required when coiling.



Frontal oblique view shows the inflated balloon (red arrow) which assists in the placement of platinum coils (yellow arrow) into the aneurysm pouch.



Final angiogram demonstrates lack of filling of the aneurysm. Three small platinum coils (white arrow) have occluded the aneurysmal pouch. Patency of both the right and left anterior cerebral arteries is preserved.

Outcomes

- On post treatment day # 1 the patient reports significant improvement of her headache.
- She has no neurological deficits
- She will continue her recovery in the NeuroICU during the next several days.

Ongoing research at UMass

- As shown in this case, this patient had significant interval growth of her anterior communicating artery aneurysm from 2012 until her current admission.
- At the New England Center for Stroke Research (<http://www.umassmed.edu/necstr/>), Dr. Matthew Gounis and his team are conducting NIH funded investigations into the causes for aneurysm growth and aneurysm rupture.
- Dr. Gounis and his team are also working on advanced imaging techniques which would help further characterize this aneurysm inflammation and growth.