

# Functional MRI

Interesting Case

Submitted by Aly H. Abayazeed, MD

48 M left parieto-temporal grade II-III astrocytoma invading left Wernicke's area showing neuronal plasticity leading to re-organization of the wernicke's area to the non-dominant right hemisphere.

#### Motor Function:

There is anterior displacement of the left precentral gyrus (motor cortex) secondary to mass effect. The motor cortex is within the anterior extension of the FLAIR hyperintensity but is more than one gyrus width from the anterior margin of the mass. Positive activation in motor cortex is noted during the right hand movement task. Lack of activation within the motor cortex in response to the right toe movement and tongue movement tasks could be due to neurovascular uncoupling or mis-registration due to patient motion during those tasks. There is mild activation in the supplementary motor area which is not involved by the FLAIR hyperintensity.

#### Language Function:

The patient is left-sided language dominant. There is robust activation in the expected location of the Broca's area on all language tasks. The Broca's area is along the anterior margin of the FLAIR hyperintensity in the left frontal lobe and is more than one gyrus width from the anterior margin of the left parietotemporal mass. Lack of activation within the expected anatomic location of the left Wernicke's area is likely due to invasion by the tumor. However, there is robust right Wernicke's area activation on the auditory response naming task with corresponding left Broca's area activation overlapping the other language tasks likely due to cortical reorganization. Positive activation is noted in relation to the language SMA.

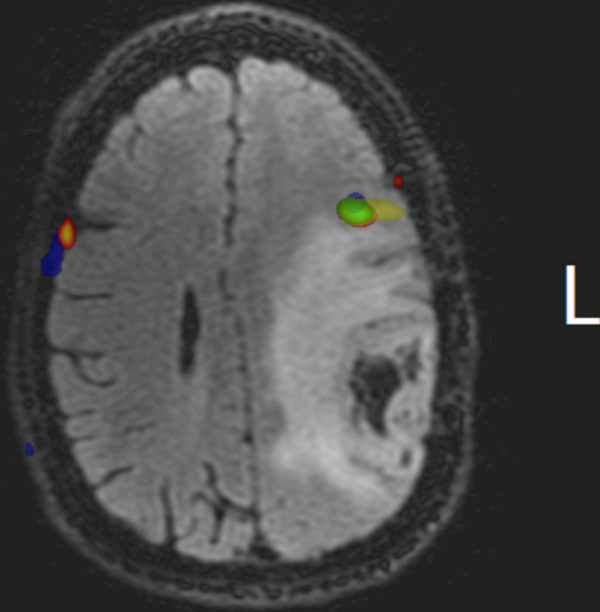
#### DTI:

The left corticospinal tract is displaced anteriorly by the mass and is draped along the anterior margin of the FLAIR hyperintensity. Mild invasion of the posterior fibers of the corticospinal tract cannot be excluded.

The left superior longitudinal fasciculus is medially displaced, mild invasion of the lateral fibers cannot be excluded.

Multiple attempts at deterministic and probabilistic tractography of the arcuate fasciculus was not successful, likely due to invasion by the tumor within the expected location of the left Wernicke's area. However, positive activation in the left Broca's area and a right wernicke' s area during the auditory response naming task suggests neuronal cortical reorganization.

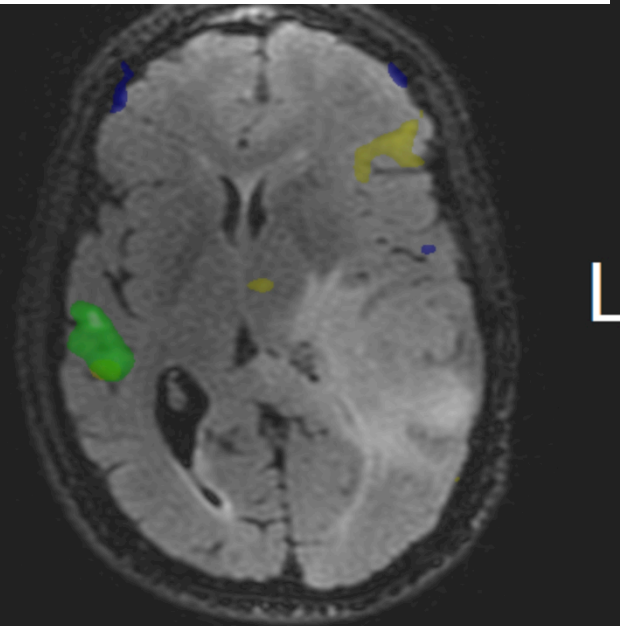
## Left Broca's activation



### BOLD info

Series	Contrast	T-value	P-value
AUDITORY RESPONSE NAMIN	[ 1 -1] Sentence completic	4.986	6.725E-06
SENTENCE COMPLETION(200	[ 1 -1] Sentence completic	4.862	1.041E-05
RHYMING	[ 1 -1] Rhying	3.246	0.001584
WORD GENERATION	[ 1 -1] Word generation	7.274	4.988E-10

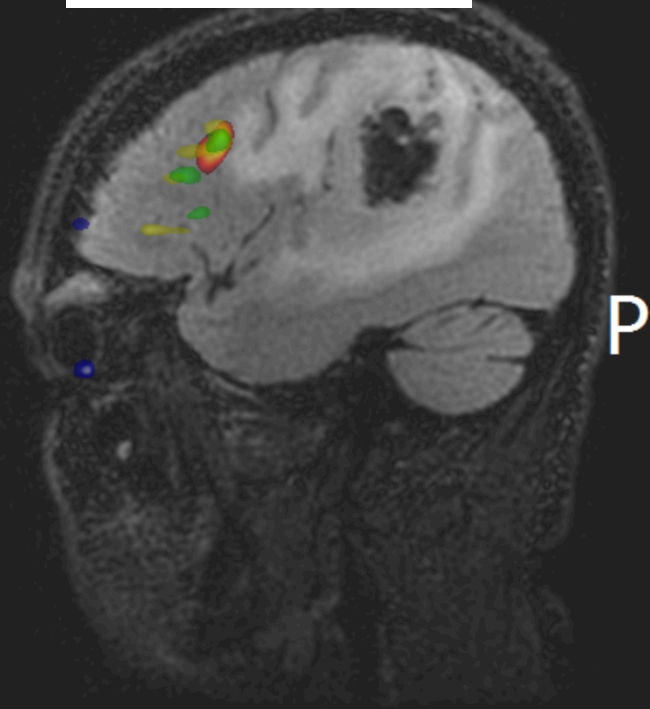
## Right Wernicke's activation due to cortical reorganization



### BOLD info

Series	Contrast	T-value	P-value
AUDITORY RESPONSE NAMIN	[ 1 -1] Sentence completic	4.986	6.725E-06
SENTENCE COMPLETION(200	[ 1 -1] Sentence completic	4.862	1.041E-05
RHYMING	[ 1 -1] Rhying	3.246	0.001584
WORD GENERATION	[ 1 -1] Word generation	7.274	4.988E-10

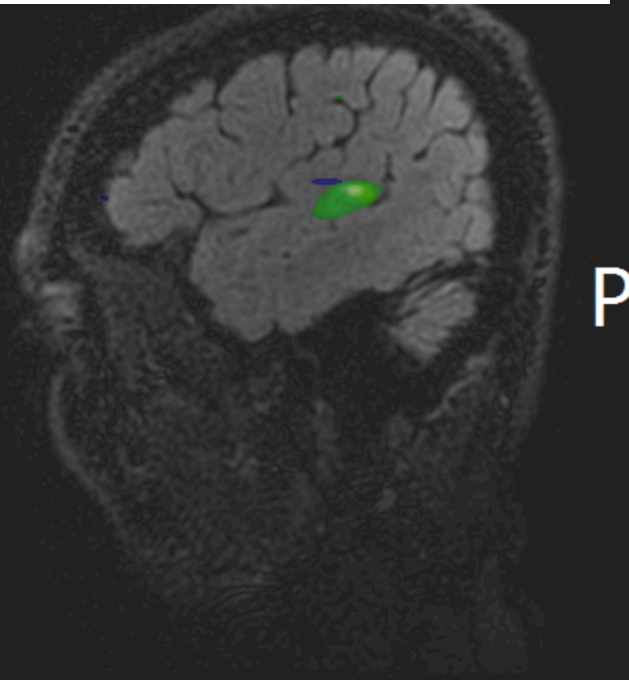
## Left Broca's activation



### BOLD info

Series	Contrast	T-value	P-value
AUDITORY RESPONSE NAMIN	[ 1 -1] Sentence completic	4.986	6.725E-06
SENTENCE COMPLETION(200	[ 1 -1] Sentence completic	4.862	1.041E-05
RHYMING	[ 1 -1] Rhying	3.246	0.001584
WORD GENERATION	[ 1 -1] Word generation	7.274	4.988E-10

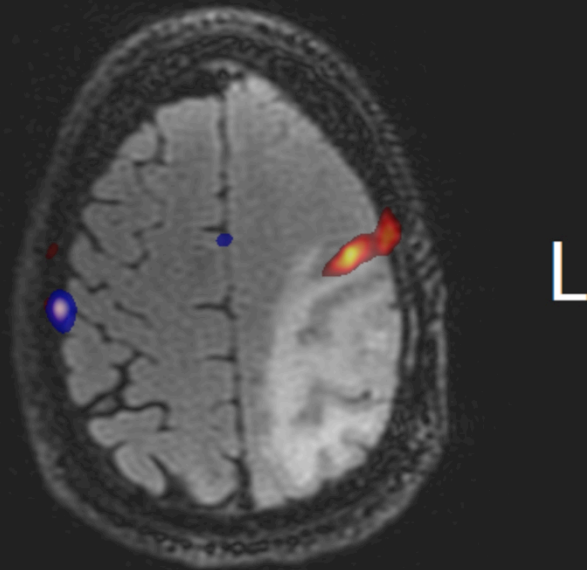
## Right Wernicke's activation due to cortical reorganization



### BOLD info

Series	Contrast	T-value	P-value
AUDITORY RESPONSE NAMIN	[ 1 -1] Sentence completic	4.986	6.725E-06
SENTENCE COMPLETION(200	[ 1 -1] Sentence completic	4.862	1.041E-05
RHYMING	[ 1 -1] Rhying	3.246	0.001584
WORD GENERATION	[ 1 -1] Word generation	7.274	4.988E-10

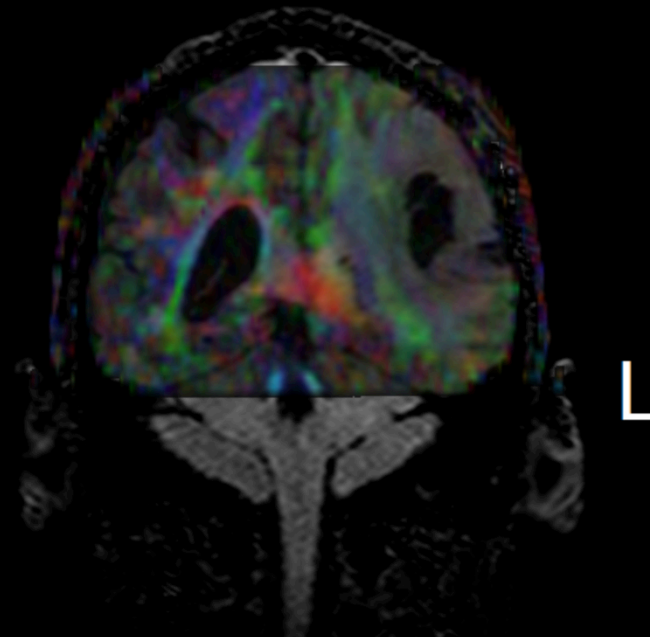
Left motor cortex activation due to right hand motion.



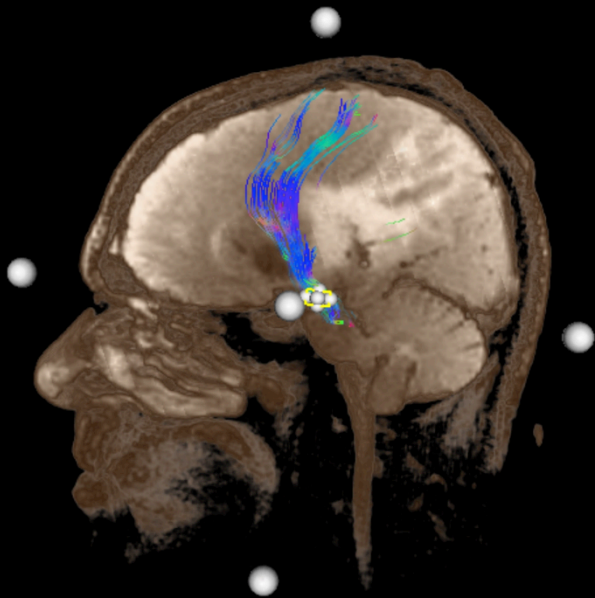
**BOLD info**

<u>Series</u>	<u>Contrast</u>	<u>T-value</u>	<u>P-value</u>
<span style="color: blue;">■</span> MOTOR TOES	[ 1 ] ON phase_1	7.451	2.252E-10
<span style="color: green;">■</span> MOTOR TONGUE	[ 1 ] ON phase_2	11.85	3.715E-18
<span style="color: red;">■</span> MOTOR FINGER	[ 1 ] ON phase	3.376	0.001222

Displacement of the brain fibers by the tumor.



Left corticospinal tract displaced anteriorly by tumor.



Left corticospinal tract displaced anteriorly by tumor. Comparison with normal location of the left CST.

